

Original Research

# TOXICITY EFFECT OF LEAF EXTRACT OF *Cassia angustifolia* ON BRAIN AND HEMATOLOGICAL PARAMETERS OF WISTAR RATS

Sabastine Aliyu Zubairu<sup>1</sup>, Olorundare Tanimola<sup>2</sup>

<sup>1</sup>Department of Pharmacology and Therapeutics, Faculty of Pharmaceutical Sciences, Gombe State University, Gombe State, Nigeria.

<sup>2</sup>Bingham university, karu, Nasarawa State, Nigeria

Received: 08 April 2025

Accepted: 04 May 2026

Published: 05 May 2026

## Abstract

**Background/aim:** plants has been the secret lock of many ailment. But understanding the sustained effect of this plant is important to avoid causing health complication. Objective: The effects of subacute *Cassia angustifolia* on the brain and blood, parameters of wistar rats were investigated in this study.

**Methods:** Rats of both sexes were employed in the experiment. In contrast to groups 2, 3, and 4, which received 50, 100, and 200 mg/kg of *Cassia angustifolia*, group 1 received distilled water (10 ml/kg). Animals were housed in standard cages for 28 days and given oral access to the extract before being weighed and scarified. The haematoxylin and eosin (H&E) staining technique was used for histological studies on the effects of the plant. The brain and heart were also meticulously taken and histologically examined. RBC, HGB, and MCV levels considerably dropped ( $P < 0.05$ ), whereas neutrophils, basophils, eosinophils, and platelets remained unaltered.

**Results:** RBC, HGB, and MCV levels considerably dropped ( $P < 0.05$ ), whereas neutrophils, basophils, eosinophils, and platelets remained unaltered. The brains of rats at 100 mg/kg were found to be slightly larger than those of control rats given 50 and 200 mg/kg. Histological examination of the brain revealed normal features at all doses.

**Conclusion:** Ethanol leaf extract of *Cassia angustifolia* showed no harmful effect to the brain tissue, thus allaying local concerns about it impact on the brain.

**Keywords:** Rat, *Cassia angustifolia*, brain, blood, RBC

**Abbreviation**

CA, *Cassia angustifolia*; DW = distilled water (WBC = white blood cells, RBC = red blood cells, HGB = hemoglobin, HCT = hematocrit, MCV = mean corpuscular volume, MCH = mean corpuscular hemoglobin, MCHC = mean corpuscular hemoglobin concentration, PLT = platelet, LYM = lymphocyte, NEUT = neutrophils, EOSI = eosinophils, BASO = basophils)

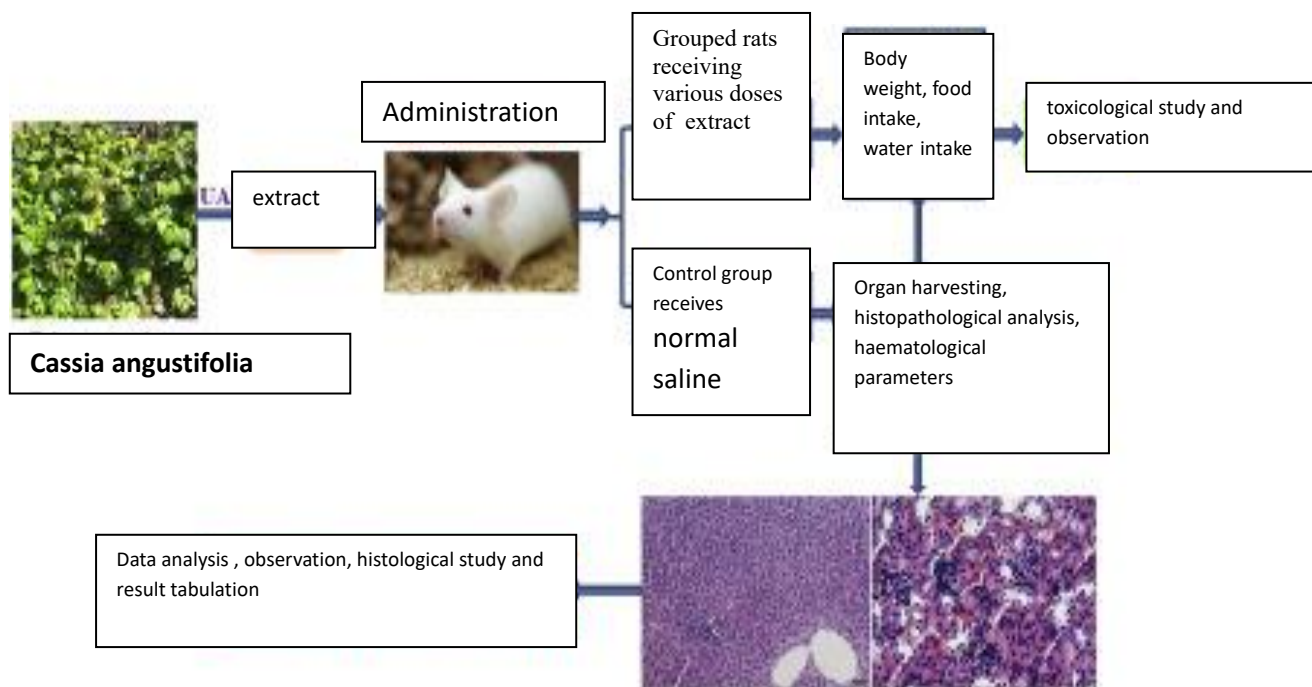
**Introduction**

The brain is the command center of the body, receiving and relaying information to other organs via the nervous system and hormones secreted by the body (Joseph et al., 2018). It governs how we think, feel, remember things, and see the world in general. Digestive chemicals are released by the stomach. Muscular tissue ridges cover the stomach. Periodic stomach muscular contractions mix the meal to aid digestion. The pyloric sphincter, a muscle valve, opens to allow food to pass from the stomach to the small intestine (Oliver-Bever 2016). The spleen is the lymphatic system's largest organ. It is a necessary organ for maintaining physiological fluid balance, yet one can live without it (Olajide et al., 1999). The grownup human brain weighs on average about 1.2–1.4 kg (2.6–three.1 lb) which is about 2% of the full frame weight,[2][3] with a extent of round 1260 cm<sup>3</sup> in guys and 1130 cm<sup>3</sup> in women.[4] there is giant character version,[4] with the standard reference variety for men being 1,one hundred eighty–1,620 g (2.60–3.57 lb)[5] and for girls 1,030–1,400 g (2.27–3.09 lb).[6]

The cerebrum, which includes the cerebral hemispheres, forms the most important a part of the mind and overlies the alternative mind systems.[7] The outer vicinity of the hemispheres, the cerebral cortex, is gray count, inclusive of cortical layers of neurons. each hemisphere is divided into four important lobes – the frontal lobe, parietal lobe, temporal lobe, and occipital lobe.[8] three different lobes are protected by way of some resources that are a primary lobe, a limbic lobe, and an insular lobe.[9] The imperative lobe contains the precentral gyrus and the postcentral gyrus and is included since it forms a awesome useful role

Extracts have been used as a laxative in modern medicine since at least the 1950s (Butler, 2004). Infants that take it accidentally may have unpleasant side effects such as severe diaper rash (Zubairu et al., 2021). Senna glycosides are abundant in the active ingredients and interact with immune cells in the colon (Joseph et al., 2019). It has been relevant for ages in management of various diseases such as insomnia, convulsion, fever, inflammation, immune and cardiovascular diseases [10,11]. There has been local report that the plant may cause oedema but there is no study on the significance of consuming the plant for a period of time on the brain. Therefore, the aim of this study is to determine the sub-acute toxic effects of *Cassia angustifolia* ethanol leaf extract on the brain of Wister rats.

**Materials and Method**



**Fig. 1: Diagrammatic representation of the process involved in toxicological study**

**Animals**

Male and female Wister rats were obtained from Bingham University's Animal House. They were fed standard animal pellets and given unlimited water. The Animal Ethics Committee of Bingham University College of Health Sciences issued authorization and approval for animal studies (BU/2021/1137). The rats (n = 6) were randomized to different treatment groups at random. Animals study were done under the same conditions. The care and handling of the animals followed established public health guidelines in Guide for Care and Use of Laboratory Animals (2011).

**Plant collection**

*Cassia angustifolia* fresh leaves were taken from its native environment in neighboring Karu village, Nasarawa State, Nigeria. The plant was verified by the Department of Botany at Bingham University in Nasarawa State, Nigeria. It was assigned the voucher number (BU1189).

**Plant extraction**

For two weeks, the leaves were shade dried. The dried plant material was then pulverized and reduced into little pieces. In 70% ethanol, the powdered material was macerated. Using a rotary evaporator, the liquid filtrates were concentrated and evaporated to dryness at 40°C under vacuum. The ethanol extract was kept at -4°C until it was used.

**Qualitative phytochemical screening**

The test was carried out according to the procedures outlined by Trease and Evans (2002). Ten percent (10%) preparation of the extract in distilled water was considered as the test samples. Distilled water was used as a negative control throughout the phytochemical tests.

**Animal study**

Twenty-four (24) rats of either sexes (weighing between 183 and 300g) were chosen at random. The extract was given to rats in groups 2, 3, and 4 at doses of 50, 100, and 200 mg/kg, respectively,

while group 1 served as the control group and received normal saline (10ml/kg). The weights of the rats were recorded at the start of the experiment and once a week thereafter. The day of sacrifice was designated as D29, whereas the initial day of dosing was designated as D0.

### **Hematological analysis**

The rats were slaughtered in accordance with protocol on the 29th day of the trial. Blood samples were obtained through cardiac puncture. Blood was drawn into sample bottles containing EDTA for hematological analysis, including hemoglobin concentration, white blood cell counts (WBC), differentials (neutrophils, eosinophils, basophils, lymphocytes, and monocytes), red blood cell counts (RBC), platelets, and hemoglobin (Hb) concentration. This was accomplished with the help of an automated hematology machine (Cell-Dyn, Abbott, USA).

### **Food and water consumption**

The difference between the daily supply of feed and water and the amount still available after 24 hours was used to compute the daily feed and water consumption. The rats were sacrificed on the 29th day of the experiment, and their organs were removed for further gross histo-pathological investigation.

### **Qualitative phytochemical screening**

The test was carried out according to the procedures outlined by Harborne [12]. Ten percent (10%) preparation of the extract in distilled water was considered as the test samples. Distilled water was used as a negative control throughout the phytochemical tests.

### **LD<sub>50</sub> determination**

Lorke [11] approach was used to perform an acute toxicity, LD<sub>50</sub> test. In two phases, a total of 13 rats weighing 100-120 g were employed.

The animals were separated into three groups of three mice each in the first stage, and the extract was supplied at three dose levels (10, 100, and 1000 mg/kg) body weight. The animals were kept under constant observation for 24 hours. Due to the lack of deaths in the first phase, extract doses of 2000, 3000, 4000, and 5000 mg/kg were used for four groups of one animal each. The animals were inspected again after 24 hours. The number of deaths (s) for each group was recorded, and the LD<sub>50</sub> was determined as follows;

$$LD_{50} = \sqrt{(D_0 \times D_{100})}$$

Where: D<sub>0</sub> = Highest dose that gave no mortality

D<sub>100</sub> = Lowest dose that produced mortality.

### **Dosage selection:**

Dosage of extract administered to animals was determined from 1/5<sup>th</sup>, 1/10<sup>th</sup> and 1/20<sup>th</sup> of the estimated LD<sub>50</sub> as described by Neharkar and Galkwad [15]..

### **Sample collection**

A heart puncture was used to collect blood samples. Blood samples were obtained in EDTA-containing sample bottles for hematological analysis and in plain bottles for biochemical analysis. Allowing the blood in the plain container to coagulate, it was centrifuged at 300rpm for 10 minutes before being split into labelled containers.

**Histological study**

brain was removed and stored in buffered formalin for 12 h before histological examination. Histopathological examination was performed using a light microscope. A histopathologist was blind to the coded treatment group and reviewed the slides. Hematoxylin and eosin staining technique was used in this study.

**Statistical analysis**

The data was expressed using the mean and standard error of the mean (SEM). Before Dunnett's post hoc test for multiple comparisons between the control and treated groups, one-way ANOVA was performed to statistically examine the data. P values of less than 0.05 were considered significant.

**Result****Phytochemical screening of *Cassia angustifolia***

Phytochemical test was carried out on the whole ethanol extract. Phytochemical screening of crude extract of *Cassia angustifolia* extract showed the presence of various chemical constitutions mostly alkaloids, Carboxylic acid, coumarins, phenol, resin, saponin, steroid sennosides, chrysophanol and anthraquinones (Table 1).

**Effect of 28 days oral administration of *Cassia angustifolia* on hematological parameters in rats.**

*Cassia angustifolia* significantly ( $P < 0.05$ ) decreased the amount of red blood cells, hemoglobin, platelets, etc. and significantly ( $P < 0.05$ ) increased the mean corpuscular hemoglobin concentration in rats at a dose level of 50 mg/kg compared to the control. The mean corpuscular hemoglobin concentration, on the other hand, had no significant ( $p < 0.05$ ) effect on basophiles, neutrophils, eosinophils, or lymphocytes (Table 2).

**Effect of 28 days oral administration of *Cassia angustifolia* on body weight (g) in rats.**

At 50 mg/kg dose level, ethanol leaf extract of *Cassia angustifolia* caused a significant ( $p < 0.05$ ) increase in body weight in the first, third, and fourth weeks, but not in the second week when compared to the control (Table 3).

**Effect of 28 days oral administration of *Cassia angustifolia* on relative organ to body weight ratio in rats.**

Rats given 200 mg/kg of the ethanol plant extract had significantly ( $p < 0.05$ ) larger brains. At higher doses of 100 and 200 mg/kg, there was no significant ( $p < 0.05$ ) change (Table 4).

**Effect of oral administration of ethanol leaf extract of *Cassia angustifolia* on histology of Brain of rats.**

The histological study of the brain indicated normal histopathological features at all doses and a modest amount of vacuolation at the 100 mg/kg extract dose. For each dose, the brain revealed normal characteristics (Figure 2).

Table 1: Results of Phytochemical Analysis of ethanol fruit extract of *Cassia angustifolia*

	Phytochemical	Crude extract
1	Tannins	—
2	Alkaloids	+
3	Diterpenes	+
4	Flavonoids	+
5	Glycosides	—
7	Saponins	+
8	reducing sugar	+
9	Terpene	+
10	Sennosides	+

**Table 2: Acute toxicity**

PHASES	DOSE (ML/KG)	MORTALITY
PHASE 1	10	0/3
	100	0/3
	200	0/3
	400	0/3
PHASE 2	500	0/1
	1000	0/1
	1500	0/1
	2000	0/1

**Table 3: Effect of 28 days ethanol leaf extract of *Cassia angustifolia***

Hematological parameters	DW(1ml/kg)	Treatment (mg/kg)		
		50 mg/kg	100 mg/kg	200 mg/kg
WBC ( $\times 10^9/L$ )	7.7 $\pm$ 0.772	7.4 $\pm$ 1.419	3.7 $\pm$ 0.657*	6.4 $\pm$ 1.085
RBC ( $\times 10^{12}/L$ )	8.2 $\pm$ 0.37	8.6 $\pm$ 0.20	6.1 $\pm$ 0.35*	7.1 $\pm$ 0.27
HGB (g/dL)	14.9 $\pm$ 0.66	14.2 $\pm$ 0.46	10.3 $\pm$ 0.76*	13.8 $\pm$ 0.77
HCT (g/dL)	54.3 $\pm$ 2.13	55.6 $\pm$ 2.75	34.7 $\pm$ 2.28*	52.4 $\pm$ 2.73
MCV (fL)	66.62 $\pm$ 0.93	65.4 $\pm$ 1.44	57.7 $\pm$ 0.31*	69.6 $\pm$ 1.72
MCH (pg)	19.1 $\pm$ 0.17	17.8 $\pm$ 1.02	18.3 $\pm$ 0.37	18.8 $\pm$ 0.20
MCHC (g/dL)	34.11 $\pm$ 0.16	32.3 $\pm$ 0.72	35.5 $\pm$ 0.53*	30.6 $\pm$ 0.74
PLT ( $\times 10^9/L$ )	626.9 $\pm$ 46.71	577.2 $\pm$ 93.32	242.3 $\pm$ 45.28*	688.4 $\pm$ 45.26
LYM (%)	76.4 $\pm$ 5.16	74.0 $\pm$ 5.19	75.8 $\pm$ 6.33	75.4 $\pm$ 5.23
NEUT ( $\times 10^9/L$ )	20.9 $\pm$ 4.57	21.8 $\pm$ 2.69	25.3 $\pm$ 5.66	21.3 $\pm$ 4.17
EOSI ( $\times 10^9/L$ )	2.6 $\pm$ 0.24	3.4 $\pm$ 0.65	2.8 $\pm$ 0.36	2.2 $\pm$ 0.51
BASO ( $\times 10^9/L$ )	2.1 $\pm$ 0.19	2.6 $\pm$ 0.85	2.4 $\pm$ 1.77	3.4 $\pm$ 1.64

\*significantly different from the distilled water (DW) control at  $p < 0.05$ . Data presented as Mean  $\pm$  SEM: n = 6,

**Table 4: Effect of 28 days oral administration of *Cassia angustifolia* on body weight (g) in rats.**

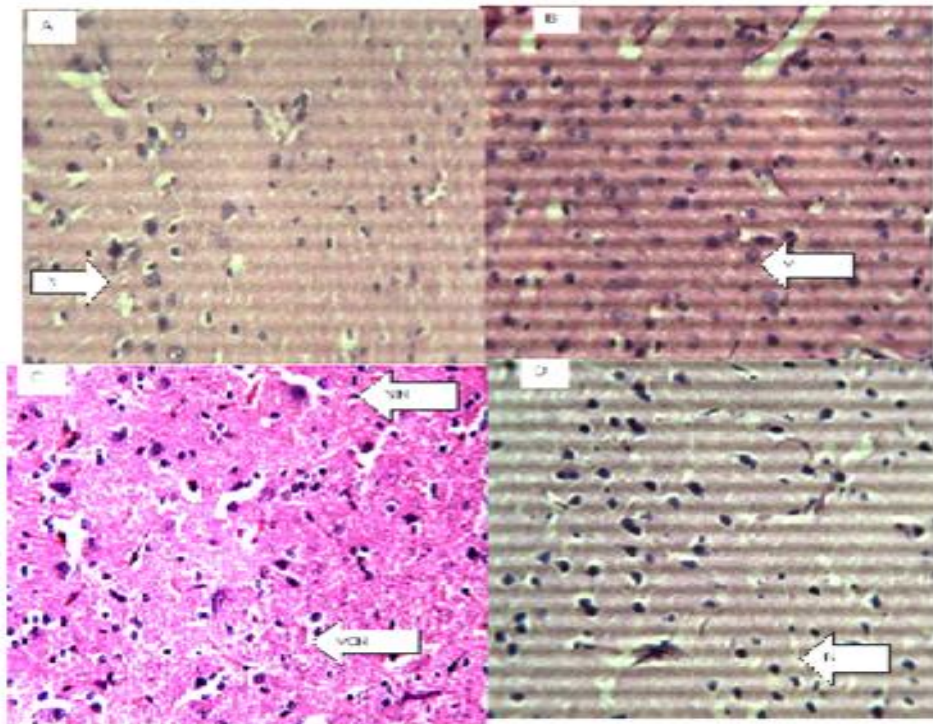
Treatment (mg/kg)	Week 1	Week 2	Week 3	Week 4
DW (10ml/kg)	197.11±6.71	196.10±6.32	194.11±5.30	192.72±9.13
50 mg/kg	199.33±10.17	196.65±15.18	197.28±3.12	173.60±5.87
100 mg/kg	206.27±19.51*	215.68±22.55	211.83±13.56*	212.10±20.40*
200 mg/kg	200.68±11.39	201.18±8.11	198.47±6.11	202.54±8.11

\*Significantly different from the distilled water (DW) control at p<0.05. DW = distilled water

**Table 5: Effect of 28 days oral administration of *Cassia angustifolia* on organ to body weight ratio rats.**

Relative organ To Body weight Ratio%	BRAIN
Treatment(mg/kg)	
DW(10 ml/kg)	0.82±0.02
50 mg/kg	0.80±0.10
100 mg/kg	0.99±0.16
200 mg/kg	0.92±0.68

\*Significantly different from the distilled water (DW) control at p<0.05. DW = distilled water



**Figure 3.** figure of the brain (Hematoxylin and eosin. H and E ×100). (a) Control group, Shows normal neurons (N). (b) 50 mg/kg. (c) 100 mg/kg (d) 200 mg/kg of ethanol stem extract of *Cassia angustifolia*

**Discussion**

The study showed that ethanol leaf extract of *Cassia angustifolia* decreased the tiers of, hemoglobin, red blood cells, hematocrit, and corpuscular volume, indicating that it could extensively reduce the blood's capability to hold oxygen and, as a result, purpose anemia. Hematological signs can be applied as meaningful indices to assess the toxicity of plant extracts in stay systems (Krenzelok et al., 2013). They also can be used to give an explanation for the outcomes of a chemical molecule or a plant extract at the blood. Anemia is a circumstance wherein the blood does not comprise enough hemoglobin, an iron-rich protein that transports oxygen into pink blood cells and offers electricity to the body, or crimson blood cells to transport oxygen from the lungs to the rest of the frame. Anemia is available in a ramification of paperwork, with varying ranges of severity and patience (Makinde and Obih 1985). The extract slightly reduced red blood cellular (RBC) and packed cell extent (PCV) levels in rats. This indicates that *Cassia angustifolia* may additionally intervene with the osmoregulatory system of blood cells and/or reason oxidative damage to the mobile membrane. The extract might also depress the haemopoietic device. The lysis of blood cells may have also had a position in the drop. RBC, PCV, hemoglobin, and lymphocytes were all lower in rats fed extracts. Hietala and colleagues (Okokon et al., 2016). The basic functions of white blood cells and their versions are to fight infections, defend the frame from outside organisms via phagocytosis, and participate in different biophysiological tactics. A lower in lymphocytes may additionally indicate that the humoral immune device is much less touchy.

In this study, rats who took an ethanol extract of *Cassia angustifolia* for 28 days had slight to near normal histological characteristics in their brain. This implies that the extract's molecules do not cross the blood-brain barrier, or that the accessible ingredient has no effect on the brain. The absence of a negative effect on the various organs suggests that the extract may not have a substantial impact on the anatomical and maybe physiological status of the organs. The plant extract most likely contains more antioxidant molecules than tissue damaging chemicals. A demanding brain damage (TBI) refers to a mind injury that is caused by an outside pressure. TBI can be as a result of a forceful bump, blow, or jolt to the top or frame, or from an object coming into the brain. not all blows or jolts to the top result in TBI. a few forms of TBI can motive transient or quick-time period troubles with mind characteristic, consisting of issues with how a person thinks, understands, movements, communicates, and acts. extra critical TBI can lead to intense and everlasting incapacity, and even death. a few accidents are considered primary, which means the harm is instantaneous. Others may be secondary, which means they could arise gradually over the route of hours, days, or weeks after harm. those secondary brain injuries are the result of reactive techniques that arise after the initial head trauma. There are two vast forms of head accidents: Penetrating and non-penetrating. There are two vast forms of head injuries: Penetrating and non-penetrating. Penetrating TBI (also known as open TBI) takes place when an object pierces the cranium (e.g., a bullet, shrapnel, bone fragment, and many others.) and enters the mind tissue. Penetrating TBI usually damages only a part of the brain. Non-penetrating TBI (also called closed head injury or blunt TBI) is caused by an outside pressure robust enough to move the brain within the cranium. reasons consist of falls, motor automobile crashes, sports accidents, blast harm, or being struck via an item.

Furthermore, tests revealed that *Cassia angustifolia* fresh and dried samples contain Sennosides A, B, C, and D, Aglycone, Rhein, Chrysophanol, Anthraquinones, steric acid, Kaempferol, and

Barbaloin (Asuzu and Chineme 1990; Tona et al., 1999). The antioxidant properties of phytomolecules such as sennosides, anthraquinones, and aglycon may have been responsible for the examined organ's decreased tissue damaging effect. Normal tissue injury may have caused by a complicated series of molecular events that include oxidative stress, inflammation, depletion of wounded cells, senescence, and the production of proinflammatory and profibrogenic cytokines. *Cassia angustifolia* extract may effect wound healing through three main mechanisms: contraction, deposition of connective tissue matrix, and epithelialization. Wounds that stay open heal through contraction; the interaction of cells and matrix results in tissue migration toward the center of the wound. Matrix deposition, is the process through which collagen, proteoglycans, and attachment proteins are deposited to produce a new extracellular matrix. Epithelialization is the process by which epithelial cells surrounding the wound edge or in residual skin appendages such as hair follicles and sebaceous glands lose contact inhibition and begin to move into the wound area via epiboly. As migration progresses, cells in the basal layers continue to proliferate, supplying more epithelial cells (Zubairu et al., 2021;joseph et al., 2018).

### **Conclusion**

The results highlight the need for caution while consuming the plant. It is also critical to determine the appropriate dose that will be beneficial for the desired purpose. More study, may be conducted to provide a better and more comprehensive understanding of *Cassia angustifolia's* potential activity in the body.

**Copyright** © 2025, Authors retain copyright. Licensed under the Creative Commons Attribution 4.0 International License (CC BY 4.0), which permits unrestricted use, distribution, and reproduction in any medium, provided the original work is properly cited. <https://creativecommons.org/licenses/by/4.0/> (CC BY 4.0 deed)

### **Acknowledgements**

We sincerely thank the editors and the reviewers for their valuable suggestions on this paper.

### **Funding**

The authors declare that no funding was received for this work.

### **References**

1. Adekunle, A. T., Akeem, A. A., Egbon, O. T., Sabastine, Z. A., Simeon, J. O., & Tosin, J. O. (2026). Evaluation of effect of *Pterocarpus santalinus* leaf extract on feed consumption, hematological and kidney indices of Wistar rats. *Caliphate Journal of Science and Technology*, 8(1), 181–188. <https://doi.org/10.4314/cajost.v8i1.19>
2. Aprioku JS, Joseph OS, Obianime AW(2016). Quantification of Antinociceptive and Anti-Inflammatory Potentials of Different *Ocimum gratissimum* Linn. Leaf Extracts in Whistar Albino Rats. *European Journal of Medicinal Plants*. Volume17(3). Page 1-8.

3. Asuzu IU, Chineme CN. (1990). Effect of *Morinda lucida* leaf extract on *Trypanosoma brucei* infection in mice. *J Ethnopharm.* 30(3):307–312.
4. Builder M.I., Joseph S.O, Olugbemi T.O. and Akande, T (2020). Toxicity. Studies of extract of African Mistletoe: *Agelanthus Dodoneifolius* Polh and Wiens in Rats. *Nigeria biomedical Journal.* Page 113-130
5. Builder MI, Anzaku SA, Joseph SO (2019). Effectiveness of intermittent preventive treatment in pregnancy with sulphadoxine-pyrimethamine against malaria in northern Nigeria. *International Journal of Recent Scientific Research* Vol. 10 (05), pp. 32295-32299.
6. Builders M, Okoli IS, Ede SO, Joseph OS, Ise UP.(2023). Evaluation of hepatoprotective activity of the aqueous extract of *Vitis vinifera* against acetaminophen-induced liver damage in rats. *Magna Scientia Advanced Research and Reviews*, 2023, 08(02), 104–110.
7. Builders M. I., Joseph S.O., Bassi PU. (2020). A Survey of Wound Care Practices by Nurses in a Clinical Setting. *International Journal of Healthcare and Medical Sciences.* Vol. 6, Issue. 5, Page 74-81.
8. Builders MI, Michael GZ, Ede SO, Joseph SO, Ise PU. (2023). Evaluation of acute and subacute toxicity of the extract of *Allium cepa* peels in Wistar rats. *World Journal of Advanced Research and Reviews*, 2023, 18(02), 1173–1180. DOI: <https://doi.org/10.30574/wjarr.2023.18.2.0839>.
9. Builders MI, Oyefeso RA, Ede SO, Joseph SO, Ise PU. (2023). Evaluation of Anxiolytic Activity of Ethanolic Extract of *Thymus vulgaris* Leaves Using Elevated Plus Maze [EPM] Test. *Journal of Advancement in Pharmacology.* Volume 3, Issue 1. 11-17.
10. Builders MI, Simeon JO, Ogundeko TO, Builders P. (2020). Antimalarial Drugs and COVID - 19. *Sumerianz Journal of Medical and Healthcare.* Vol. 3, No. 12, pp. 111-116.
11. Builders MI, Udeh BO, Ede SO, Joseph SO, Ise PU. (2023). Evaluation of anti-ulcer activity of methanolic extract *Combretum paniculatum* Vent. in rats and mice using pylorus–ligation induced model. *Open Access Research Journal of Life Sciences.* 05(02), 010–020. DOI: <https://doi.org/10.53022/oarjms.2023.5.2.0023>.
12. Builders MI, Udeh BO, Ede SO, Joseph SO, Ise PU. (2023). Evaluation of anti-ulcer activity of methanolic extract *Combretum paniculatum* Vent. in rats and mice using pylorus–ligation induced model. *Open Access Research Journal of Life Sciences*, 05(02), 010–020.
13. Butler, M. S. (2004) The role of natural product in chemistry in drug discovery. *J. Nat. Prod.* 67: 2141–2153.
14. Duke, James (2012). *Handbook of Legumes of World Economic Importance.* Springer Science & Business Media. p. 49.
15. Emily M. Toxicity. In: Cutler J, (2007). editor. In: *Encyclopedia of Earth.* Cleveland, Washington D.C.
16. Etuk IC, Udobang JA, Daniel AO, Ekong O, Okokon JE, Joseph OS. (2023). Effect of leaf extract and fractions of *Solanum anomalum* on oxidative stress markers, kidney function indices and histology of alloxan-induced diabetic rats. *Journal of Current Biomedical Research.* Vol 3. Page 783-799. <https://doi.org/10.54117/jcbr.v3i1.4>

17. Gray's Anatomy 2008, pp. 242–244.
18. Haruna WC, Builders M, Simeon JO, Tosin JO. (2020). Toxicological Study of the Effect of Ethanol Leaf Extract of *Pterocarpus santalinus* Extract on Liver of Wister Rats. *Nigeria biomedical Science Journal*. Page 17-29.
19. Haruna WC, Simeon JO, Builders M, Tosin JO(2020). Effect of ethanol leaf extract of *cassia angustifolia* extract on heart and lipid profile of wister rats. *African Journal of Pharmaceutical Research & Development*. Vol. 12 No.1. Page 1-8.
20. Ise, U.P., Oyepata S.J., Famojuro, T.I., Johnson O.J., Sebastine A. Z, Ibrahim, A.M1., Williams Ujah and Builders, M.I. (2023). 60-Day Assessment of Mr. Flush® Cleanser on Hematological indices and Kidney Histoarchitecture in Exposed Wistar Rats. *J. Pharm. Sci. & Res.* Vol. 15(5), 2023, 1135-1141.
21. Joseph O. S. and Joseph O. T. (2018). Hepatoprotective activity of ethanol stem extract of *Homalium letestui* against thioacetamide-induced liver injury. *The Nigerian Journal of Pharmacy*. Vol. 52 (1). Page 67-74. <https://psnnpj.org/index.php/home/article/view/38>
22. Joseph O. S., Builders M., Joseph O. T. (2020). Effect of Caffeine on Diazepam - Induced Sedation and Hypnosis in Wister Rat. *Global Scientific Journal*. Vol. 8, Issue 9. Page 451-466
23. Joseph O. S., Builders M., Joseph O. T., Sabastine A.Z. (2020). Assessing differential impacts of COVID-19 on African countries: A comparative study. *International Journal of Research and Innovation in Applied Science*. Vol. 5, Issue 5. Page 197-203
24. Joseph O. S., Joseph O. T., Musa T. L and Oyepata P. J. (2019). Histological evaluation of the nephroprotective activity of the ethanol stem extracts of *Homalium letestui* in Gentamicin – induced albino rats injury, using various staining techniques. *Global Scientific Journal*. Volume 7, Issue 8. Page 1065-1087.
25. Joseph O. S., Jude E.O and Joseph O. T. (2018). Hepatoprotective activity of extract of *Homalium Letestui* stem against carbon tetrachloride-induced liver injury. *Advance Herbal Medicine*. Vol4(4), Page 1-11. [http://futurenatprod.skums.ac.ir/article\\_45846\\_6c859a83226bb82b7d35947e75efb91c.pdf](http://futurenatprod.skums.ac.ir/article_45846_6c859a83226bb82b7d35947e75efb91c.pdf)
26. Joseph O. Simeon., Joseph O. Tosin., Sabastine A. Zubairu. (2023). Evaluation of the Effect of *Anacardium Occidentale* Cashew Apple Juice on Kidney of Gentamicin Induced Injury in Albino Rats, *Journal of Clinical and Laboratory Research*. 6(1); DOI:10.31579/2768-0487/100
27. Joseph O.S., Builders M., Emem E.U and Joseph O.T. (2019). Effect of ethanol leaf extract of *cassia angustifolia* extract on liver of wister rats. *Global Scientific Journal*. Volume 8, Issue 9. Page 1112-11120.
28. Joseph O.S., Builders M., Emem E.U and Joseph O.T. (2019). Effect of ethanol leaf extract of *Cassia angustifolia* extract on kidney of Wister Rats. *Global Scientific Journal*. Volume 7, Issue 10. Page 106-122.

29. Joseph O.S., Builders M., Joseph O, T., Zubairu S. A., Musa T. (2019). Sub-Acute Toxicity Study of Ethanol Leaf Extract of *Ocimum Canum* on Liver of Wister Rats. *International Journal of Research and Scientific Innovation*. Volume VI (V). Pp. 364-369.
30. Joseph O.T., Joseph O. S., Chinwe A. F. (2021). Clinical Study on the Effect of *Moringaoleifera* on Body mass index, Serum Level of High density lipoprotein and Triglyceride in Subjects Taken Tenofovir, Lamivudine and Efavirenz Combination Regimen. *J RNA Genom 2021* Volume S04 Issue 004. Page 1-6.
31. Joseph OS , Builders M , Joseph O T , Famojuro TI, Ogira JO, Moses FD, Musa TL. (2021). Effect of the Demographic of Covid-19 on Different Countries; Using the USA for Comparism. *International journal of multidisciplinary research and analysis*. Volume 04 Issue 02. Page 193-203.
32. Joseph OS, Builders M, Joseph OT, Ariahu EC, Zubairu SA, Musa T, and Joseph OP. (2019). Toxicity study of ethanol leaf extract of *ocimum canum* on heart and lipid profile of wister rats. *International Journal of Current Advanced Research*. Volume 8. (Issue 05). Page 18800 – 18803. DOI: <http://dx.doi.org/10.24327/ijcar.2019.18803.3601>
33. Joseph OS, Builders M, Joseph OT, Sabastine AZ, Musa TI and Oyepata PJ. (2019). Sub-acute toxicity study of ethanol leaf extract of *Ocimum canum* on the kidney of wistar rats. *African Journal of Pharmaceutical Research & Development*. Vol. 11 No.1. Page 1-7.
34. Joseph OS, Builders M, Joseph OT, Sabastine AZ, MUSA TL and Oyepata PJ. (2019). Sub-acute toxicity study of ethanol leaf extract of *Ocimum canum* on brain, lungs, stomach and spleen of wister rats. *African Journal of Pharmaceutical Research & Development*. Vol. 11 No.1. Page 35-42.
35. Joseph OS, Joseph OT. (2023). Toxicological studies of ethanol leaf extract of *Lavandula stoechas* on kidney of Wistar rat. *Journal of Current Biomedical Research* Vol 3. Page 942 -956. DOI: <https://doi.org/10.54117/jcbr.v3i2.11>.
36. Joseph OT, and Joseph OS. (2024). Sub-chronic Toxicological evaluation of extract of *Lavandula stoechas* on Liver, haematological parameters, and feed consumption of Wistar rats. *Tanzania Journal of Health Research*. Volume 25: Number 3. Pages 1233-1242
37. Joseph OT, Joseph OS, Adegbuyi AT. (2024). Biochemical and Histological Evaluation of Sub-Chronic Administration of *Canscora decussate* Leaf Extract on Liver and Heart of Wistar Rats. *Trop J Phytochem Pharm. Sci.* 2024; 3(5): 380 – 385 <http://www.doi.org/10.26538/tjpps/v3i7.4>
38. Joseph Oyepata Simeon, Joseph OpeyemiTosin, SabastineAliyuZubairu. (2023). Evaluation of the Effect of *AnacardiumOccidentale* Cashew Apple Juice on Kidney of Gentamicin Induced Injury in Albino Rats. *Journal of Clinical and Laboratory Research*. Volume 6(1. Page 1-8. DOI:10.31579/2768-0487/100
39. Joseph Oyepata Simeon, Joseph OpeyemiTosin, SabastineAliyuZubairu. (2023). Toxicological study of *Bauhinia variegata* (linn.) on Kidney of wistarrat. Accepted for publication
40. Joseph Oyepata Simeon, Joseph OpeyemiTosin, Samuel Sunday Agboola, AdegbuyiTheophilusAdekunle, AgboolaOluwaseun Emmanuel, OlusolaAbayomi John,

- AdeyemiAkinyemi Patrick. (2023). Investigating Clinical potential of Moringaoleifera on the cholesterol, BMI and blood triglyceride level in HIV/AIDs patient on Antiretroviral Combination Regimen. *J. Pharm. Sci. & Res.* Vol. 15(5), 2023, 1101-1108.
41. Joseph SO, Okokon JE and Joseph OT. (2018).Effect of ethanol stem extract of *homaliumletestuion* gentamicin-induced kidney Injury in rat. Vol. 4(2). *Advanced Herbal Medicine*. Page 51-64.[http://futurenatprod.skums.ac.ir/article\\_35305\\_fda963b4a327090b76dc3dec11eb656f.pdf](http://futurenatprod.skums.ac.ir/article_35305_fda963b4a327090b76dc3dec11eb656f.pdf)
  42. Joseph SO, Opeyemi JT. (2021). Effect of Clinical Study of Moringaoleifera on Body mass index, Low density lipoprotein and Triglyceride level in Patients on Tenofovir/lamivudine/efavirenz Combination Therapy. *Advanced Herbal Med.* Vol. 6. Issue 1. Page. 14-2.
  43. Joseph, O. S. (2026). COVID-19 immunological consequences: immunological significance of viro-allergy-hygiene hypothesis. *Expert Review of Clinical Immunology*, 1–12. <https://doi.org/10.1080/1744666X.2026.2664060>
  44. Joseph, O. S., Joseph, O. T., El-Gazzar, A. M., Mahmoud, M. H., Omoirri, M. A., & Gaber, E. S. B. (2024). Toxicological evaluation of ethanol leaf extract of *Pterocarpus santalinus* on lungs, stomach, brain and hematological parameters of Wistar rats. *Cogent Food & Agriculture*, 10(1), 2303828.Link: <https://www.tandfonline.com/doi/full/10.1080/23311932.2024.2303828>
  45. Joseph, O. S., Omoirri, M. A., & Joseph, O. T. (2024). Evaluation of the phytochemical Constituent, acute toxicity and antiulcer activity of *Duranta erecta* fruit extracts. *Journal of Herbs, Spices & Medicinal Plants*, 30(4), 321–332. <https://doi.org/10.1080/10496475.2024.2359430>
  46. Modupe BI, Simeon JO, Tosin JO. (2022). Toxicological study of ethanol extract of *Lavandula stoechas* on Liver of Wistar rat. *International Journal of Advances in Engineering and Management (IJAEM)* Volume 4, Issue 9. pp: 892-901.
  47. Modupe IB, SOyepata SJ, Akpobome RV (2019). Effect of *Parkia biglobosa* extract on open skin woundhealing in dexamethasone- induced hyperglycaemia and histological assessment in rats. *African Journal of Pharmacy and Pharmacology*. Vol. 13(8), pp. 84-89.
  48. Molina, D. Kimberley; DiMaio, Vincent J. M. (2015). "Normal Organ Weights in Women". *The American Journal of Forensic Medicine and Pathology*. 36 (3): 182–187.
  49. Okokon JE. O, Joseph OS.andUmoh EE. (2016). Hepatoprotective activity of *Homaliumletestui* stem extract against paracetamol liver injury. *Avicenna Journal of Phytomedicine*. 13(4): 87 – 92.
  50. Okokon JE., Joseph OS. andUmoh EE. (2016). Nephroprotective activity of *Homaliumletestui* stem extract against paracetamol induced kidney injury. *Journal of Experimental and Integrative Medicine*. Volume 6 (1): 38-43.**DOI:** 10.5455/jeim.250216.or.147
  51. Olajide OA, Awe SO, Makinde JM, Morebise O. (1999). Evaluation of the Anti-diabetic Property of *Morinda lucida* Leaves in Streptozocin-diabetic Rats. *J Pharm Pharmacology*. 51(11):1321–1324.

52. Oliver-Bever B. (2016). *Medicinal Plants in Tropical West Africa*. Cambridge: Cambridge University Press. pp. 89–90.
53. Oluwakanyesola A. S., Joseph O. S., Jacob A., Rebecca S. M. and Joseph O. T. (2018). Sub-acute haematological toxicity study of safi® blood purifier on wister rats. *The Nigerian Journal of Pharmacy*. Volume 52 (20).
54. Omoirri MA, Oloche JJ, Nkechi JO, Amarachukwu UO, Ibeh CN, Jegi IF, Obi DM, Chukwunonso CO, Joseph OS, Adegbuyi, AT, Joseph OT, Zubairu SA. (2024). Antidiabetic activity of methanol leaf extract of *Manihot esculenta* crantz (cassava leaf) in alloxan induced diabetic mice: A Potential Alternative for Diabetes Mellitus treatment. *Afr.J.Bio.Sc.* 6(14). Pg 12429 to 10. doi: 10.48047/AFJBS.6.14.2024.12428-12450
55. Opeyemi JT, Oyepata JS, Sabastine ZA and Chukwuebuka OF. Haematological and Histopathological Effects of Ethanol Extract of *Bauhinia variegata* (Linn.) on the Brain, Lungs and Spleen of Wistar Rats *Trop J Nat Prod Res.* 2025; 9(4) 1672 – 1677  
<https://doi.org/10.26538/tjnpr/v9i4.41>
56. Oyebadejo S. A, Joseph O. S, Adesite S. O and Omorilewa A.O. (2019). Effect of Citrus Limon Juice and Tamoxifen on the Tumour growth mass Indices, Cell Proliferation, Cell Viability and Cytogenetic (Mitotic Index) of Sprague Dawley Rats Induced MCF-7 Breast Cancer Cells. *Saudi Journal of Biomedical Research.* (4). Pg. 216 - 225.DOI:10.21276/sjbr.2019.4.5.4
57. Oyebadejo S. A, Joseph O. S, Adesite S. O and Omorilewa A.O. (2019). Effect of Citrus Limon Juice and Tamoxifen on the Tumour growth mass Indices, Cell Proliferation, Cell Viability and Cytogenetic (Mitotic Index) of Sprague Dawley Rats Induced MCF-7 Breast Cancer Cells. *World Journal of Pharmacy and Pharmaceutical Sciences.* (4). Pg. 216 - 225.DOI:10.20959/wjpps20197-14087
58. Oyepata JS and Adekunle AT. (2024). Haematological, Renal and Gastric Effects of Ethanol Leaf Extract of *Bauhinia variegata* Linn. *Trop J Phytochem Pharm. Sci.* 3(2):174-178.  
<http://www.doi.org/10.26538/tjpps/v3i2.3>
59. Oyepata JS and Opeyemi JT. (2024). Evaluation of Proliferative Potential of *Musa Paradisiaca* Stem Juice on the Pancreatic Cells of Wistar Rats. *Trop J Nat Prod Res.* 2024; 8(1):6035-6038.  
<http://www.doi.org/10.26538/tjnpr/v8i1.46>
60. Oyepata JS, Opeyemi JT, Adekunle AT, Moses OA. (2024). Effect of *Pterocarpus santalinus* Ethanol Leaf Extract on Haematological, Histopathological and Lipid Profile Indices in Wistar Rats. *Trop J Nat Prod Res.* 2024; 8(3):6681-6685. <https://doi.org/10.26538/tjnpr/v8i3.30>
61. Sabastine AZ , Joseph OS , Joseph OS, Famojuro TI, Olorunfemi AF. (2021). Effect of Cashew apple juice (*Anacardium occidentale* L.) on Hematology and Spleen of Gentamicin Induced Injury in Albino Rats. *Global Scientific Journal*. Volume 9, Issue 7. Page 3686-3698.
62. Sabastine AZ, Musa TL, Joseph OS, Builders M, Joseph OT. (2019). Histological study of effect of ethanol stem extracts of *Homalium letestui* in paracetamol induced injury in albino rat, using various staining techniques. *American Journal of Biomedical Science & Research.* 4(2). Page 82 – 89.DOI:10.34297/AJBSR.2019.04.000768

63. Simeon JO, Builders M, Haruna WC, Tosin JO, Zubairu SA, Lubo MT. (2019). Effect of administration ethanol leaf extract of terminaliachebula on liver of wister rat. *International Journal of Research and Scientific Innovation*. Volume VI (Issue VII). Page 91-97.<https://www.rsisinternational.org/journals/ijrsi/digital-library/volume-6-issue-7/91-97.pdf>
64. Simeon JO, Modupe B, Haruna WC, Zubairu SA, Lubo MT, Tosin JO. (2019). Histological study of effect of ethanol stem extracts of Homalium letestui on thioacetamide - induced injury in albino rat, using various staining techniques. *International Journal of Research and Scientific Innovation*. Volume VI (Issue VII). Page 77 – 85.<https://www.rsisinternational.org/journals/ijrsi/digital-library/volume-6-issue-7/77-85.pdf>
65. Simeon JO, Simeon JO, Zubairu SA, Adegbenga AD(2021). Concomitant administration of ethanol leaf extract of *Thymus vulgaris* on Diazepam– induced Sedation and Hypnosis in Wister Rat. *Journal of Nursing and Health Science*. Volume 16, Issue 5. PP 04-09.
66. Simeon JO, Tosin JO, Adegbenga AD. (2021). The Relative Global Consequences of Cumulative Distribution of Covid-19, Using the USA as Comparison Factor and Cumulative Covid -19 Data of 31st October 2021. *International Journal of Multidisciplinary Research And Analysis*. Page 1906 -1917.
67. Simeon JO, Tosin JO, Zubairu SA (2023). Characteristic Effect of Cashew Apple Extract of *Anacardium occidentale* on Liver of Gentamicin Induced Injury in Albino Rats. *J Tradit Med Clin Natur* 12: 386. DOI: 10.4172/2573-4555.1000386
68. Simeon JO, Tosin JO. (2024). Evaluation of synergistic cytotoxic potential of *Zingiber officinale* and *Allium sativum* on Wistar rats Testes. *JOPAT Vol* 23(1), 1208 – 1219.
69. Simeon JO, Zubairu SA, Tosin JO(2021). Clinical evaluation of the potential benefits of taking *Moringa oleifera* on blood triglyceride and cholesterol level in patient taking Tenofovir/Lamivudine/Efavirenz (TLE) combination. *Journal of Pharmaceutical Science & Research*. Vol. 13(10), 623-629.
70. Simeon JO, Zubairu SA, Tosin JO. (2023). Nephroprotective effect of *Anacardium occidentale* (cashew) apple juice on kidney
71. Simeon JO.,Lubo MT., Tosin JO. , Irabor I. (2020). The Dynamics of Differential Impacts of COVID-19 on African Countries Compared to Other Parts of the World. *International journal of multidisciplinary research and analysis*. Volume 03 Issue 11. Page 185-198.
72. Simeon JS, Builders M, Deborah IR, Zubairu SA, Lubo MT, Philip OJ, Tosin JT, Haruna WC. (2019). Sub-Acute Toxicity Study of Ethanol Leaf Extract of *Terminaliachebula* On Brain, Stomach and Spleen of Wister Rats. *American Journal of Biomedical Science & Research*. 3(3). Page 277-282.
73. Simeon, J. O., & Tosin, J. O. . (2025). Comparative Phytochemical Analysis of Citrus medica fruit juice and peels. *Caliphate Journal of Science and Technology*, 7(3), 326–331. <https://doi.org/10.4314/cajost.v7i3.2>
74. Simeon, J.O., J.O. Tosin and S.A. Zubairu, (2023). Update report on progress of COVID-19 pandemic from 19th-25th January, 2022 across different countries of the world. *Asian J. Appl. Sci.*, 16: 55-63. DOI: 10.3923/ajaps.2023.64.71.

75. Simeon, J.O., J.O. Tosin and S.A. Zubairu, 2023. Update report on progress of COVID-19 pandemic from 19th-25th January, 2022 across different countries of the world. *Asian J. Appl. Sci.*, 16: 55-63.
76. Simeon, JO, Tosin JO. (2024). Toxicological Evaluation of Sub-Chronic Administration of Ethanol Leaf Extract of *Ocimum canum* on Lipid Parameters, Heart Histology and Feed Consumption of Wistar Rats. *Caliphate Journal of Science and Technology Journal/Caliphate Journal of Science and Technology/Vol. 6 No. 1*. Pp. 70-76.
77. Smeon JO, Zubairu SA, Tosin JO. (2021). Global Implication of Differential Impacts of Covid-19 on Different Countries Using the USA as A Comparism Factor. *Journal of Nursing and Health Science*. Volume 10, Issue 5. PP 36-44.
78. Solomon, I.P, Oyebadejo, S.A., Ukpo E.M. and Joseph, O.S. (2015). Changes in serum electrolyte, creatinine and urea of fresh Citrus limon juice administered to growing rabbits (*Oryctolagus cuniculus*). *International Journal of Agricultural Science Research*. Vol. 4(8), pp. 180-183.
79. Solomon, I.P, Oyebadejo, S.A., Ukpo E.M. and Joseph, O.S. (2015). Effect of Fresh Citrus limon Juice on Liver Histomorphology of Growing Rabbits (*Oryctolagus cuniculus*). *Scholars Journal of Agriculture and Veterinary Sciences*. 2(5):347-351. <http://saspjournals.com/sjavs>
80. Sun, BL; Wang, LH; Yang, T; Sun, JY; Mao, LL; Yang, MF; Yuan, H; Colvin, RA; Yang, XY (April 2018). "Lymphatic drainage system of the brain: A novel target for intervention of neurological diseases". *Progress in Neurobiology*. 163–164: 118–143
81. Timothy S.Y., Wazis C.H., Midala T.A. S, Joseph O.S., Sabastine A.Z., Nachanaa T. and Oiza F.D. (2017). Evaluation of Anti-Diarrhoeal Activity of Different Bark Extracts of *Faidherbia albida* (Delile) A (Chav) in Albino Rats. *Bima Journal of Science and Technology* Vol. 1 ( 2). Pg. 122-130
82. Tona L, Ngimbi NP, Tsakala M, Mesia K, Cimanga K, Apers, De Bruyne T, Pieters L, Totte J, Vlietinck AJ. (1999). Antimalarial activity of 20 crude extract from nine African medicinal plants used in Kinshasha. *Congo J Ethnopharm*. 68(1-3):193–203.
83. Tosin JO, Simeon JO, Zubairu SA. (2023). Genetic, demographic and virology study on active and mortality cases of COVID-19 across different countries of the world as at 12th October 17, 2022. *J RNA Genomics*. 2023 Volume 19 Issue 3. DOI:10.35841/2591-7781.19.3.135
84. Tosin JO, Wolfe OA, Iyeopu SM, Simeon JO, Chinwe A, Lubo MT. (2019). Clinical study on the effect of *Moringa oleifera* on serum level of glucose and tryglyceride in subjects taken tenofovir, lamivudine and efavirenz combination regimen. *European Scientific Journal*. Vol.15, (.21). Page 280 -293. Doi:10.19044/esj.2019.v15n21p280 URL:<http://dx.doi.org/10.19044/esj.2019.v15n21p280>
85. Tosin JO, Zubairu SA, Simeon JO. (2021). Clinical Effect of *Moringa oleifera* on Body Mass Index, Triglyceride and High Density Lipoprotein in Subjects Taken Tenofovir Combination Regimen. *European Journal of Biology and Medical Science Research*. Vol.9, No.4, pp.6-19.
86. Trease GE, Evans WC. *Pharmacognosy*. 15th Ed. London: Saunders Publishers; 2002. pp. 42–44. 221–229, 246–249, 304–306, 331–332, 391–393.

87. Wazis CH, Joseph OS, Modupe B, Joseph OP (2020). Effect of Ethanol Leaf Extract of *Pterocarpussantalinus* Extract on Kidney of Wister Rats. *Nigerian Biomedical Science Journal* Vol. 17 No 1. Page 35-47.
88. Yankova, Galina; Bogomyakova, Olga; Tulupov, Andrey (November 1, 2021). "The glymphatic system and meningeal lymphatics of the brain: new understanding of brain clearance". *Reviews in the Neurosciences*. 32 (7): 693–705.
89. Yankova, Galina; Bogomyakova, Olga; Tulupov, Andrey (November 1, 2021). "The glymphatic system and meningeal lymphatics of the brain: new understanding of brain clearance". *Reviews in the Neurosciences*. 32 (7): 693–705.
90. Zubairu SA, Festus OA, Simeon JO, Irabor I, Tosin JO. (2021). Effect of *Anacardium occidentale* Fruit Juice Extract on Haematological Parameters and Spleen of Paracetamol Induced Injury in Albino Rats. *Global Scientific Journal*. Volume 9, Issue 7. Page 1640-1654.
91. Zubairu SA, Festus OA, Simeon JO, Irabor I, Tosin JO. (2021). Effect of *Anacardium occidentale* Fruit Juice Extract on Haematological Parameters and Spleen of Paracetamol Induced Injury in Albino Rats. *Global Scientific Journal*. Volume 9, Issue 7. Page 1640-1654.
92. Zubairu SA, Simeon JO, Tosin JO (2021). Effect of ethanol leaf extract of *Terminalia chebula* extract on kidney of wister rats. *Global scientific Journal*. Volume 9, Issue 2. Page 514-526.
93. Zubairu SA, Simeon JO, Tosin JO (2021). Effect of ethanol leaf extract of *Terminalia chebula* extract on kidney of wister rats. *Global scientific Journal*. Volume 9, Issue 2. Page 514-526.